

SEM investigations regarding skin micromorphology and modification induced by bacterial infections in *Cyprinus carpio* and *Salmo trutta fario*

Irina Neta Gostin, Anca Narcisa Neagu and Vasile Vulpe

Abstract— The micromorphology of the epidermis of the common carp (*Cyprinus carpio*) and brown trout (*Salmo trutta fario*) was investigated by scanning electron microscopy (SEM). The external part is unilayered and the outer surface presents microridges ornamentations. The increased preoccupations in fish culture have increased the interest regarding with the bacteria that affect fish health, growth, and survival. In this study SEM was used for the characterization of the skin bacterial lesions and of modifications induced by them.

Keywords— Bacteria, *Cyprinus carpio*, Fish skin, *Salmo trutta fario*, SEM

I. INTRODUCTION

INCREASED preoccupations in fish culture have increased the interest regarding with the bacteria that affect fish health, growth, and survival [1, 2, 3]. Fish skin is an important defense system against pathogens because they are in contact with numerousness microorganisms in the aquatic habitat. Fish skin poses high developed antimicrobial defences mechanisms [4]. The antibacterial role of fish skin mucus has been known for many years [5]. It contain antimicrobial, bioactive substances including lysozyme, complement, C-reactive protein, hemolysins and lectins and the epidermal migration of inflammatory cells and their secretions which is of interest in regard to fish immunity [2, 7, 8, 9]. The mucus plays a role in the prevention of colonization by parasites, bacteria and fungi [10]. Ulcerative lesions in fish are usually a consequence of bacterial, viral or fungal pathogens, or parasites.

Aeromonas is among the most common bacteria in freshwater habitats throughout the world, and these bacteria frequently cause disease among cultured fishes [11, 12]. It is the predominant bacteria isolated from the hemorrhagic lesions and necrotic ulcers in fish skin [13]. Bacteria infection of fish constitutes a huge menace for aquaculture farming, leading to disastrous economic loss and health risks for the consumer [14].

Aeromonas are often referred to as a complex of disease organisms that are associated with bacterial hemorrhagic septicemias and other ulcerative conditions in fishes [11, 15]. These bacteria can cause the following diseases: furunculosis of salmonids, goldfish ulcer disease, carp erythrodermatitis, and trout ulcer disease.

Fish bacteriosis was investigated by numerousness authors by histological, microbiological and taxonomical point of view [16, 15]. Since the 1980s, molecular methods have provided useful tools for diagnostic microbiology as well as for taxonomic and epidemiological studies on pathogenic bacteria [17].

Few scanning electron microscopy investigations were finding in the literature regarding the lesions produced by bacteria in general and *Aeromonas* in particular [18]. Martínez and collaborators [19] characterize by scanning electron microscopy the lesions produced through an experimental infection of *Flavobacterium psychrophilum* in fins of Atlantic salmon *Salmo salar*.

The aim of this paper is to present the electrono-microscopic details of the bacteria induced lesions and to underline the importance of these investigations in fish bacteriosis study. The lesions were observed by scanning electron microscopy in order to investigate the invasion of bacteria in the skin tissue.

II. MATERIAL AND METHODS

The fish was sampled from Ezăreni Research Station for Aquaculture Development and Aquatic Ecology (Iasi country) in August, 2009 (for *Cyprinus carpio*) and from a private farm in Bicaz (Neamt country) in August 2010 (for *Salmo trutta fario*). Lesions by different sizes were noted on the ventral region, on the side of the abdomen or on the caudal peduncle. The gross lesions consisted of focal erythema was well-delimited ulcers with necrotic centers. A healed lesion was sampled from a caudal region of an individual of *Cyprinus carpio*.

This work was supported by National Center of Programs Management Romania, Project PN II Partnerships 52138/2008.

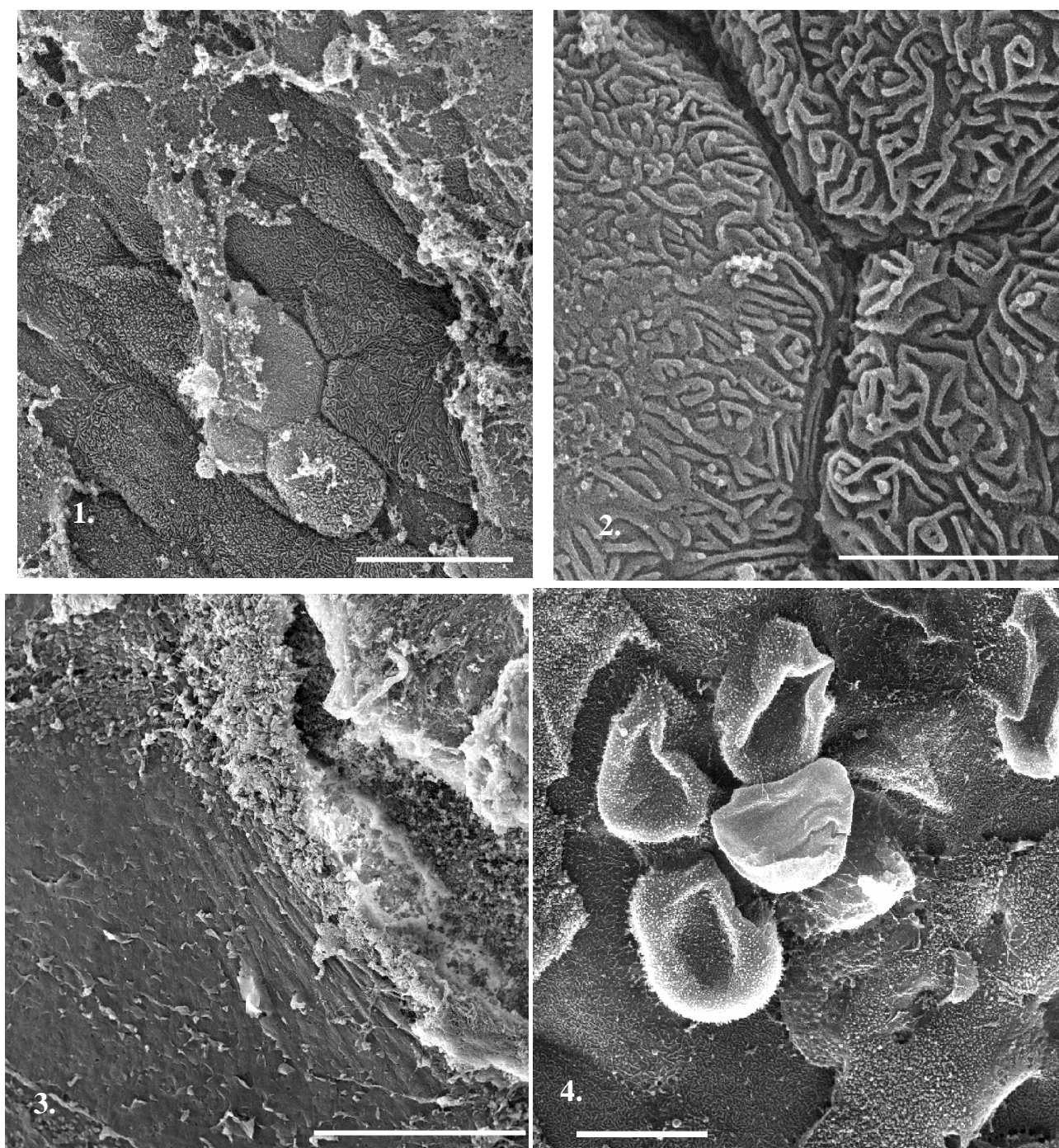


Fig. 1 – General aspect of the normal skin in *Cyprinus carpio* (scale bar = 200 μ), Fig. 2 – Detail from epithelial cells of the normal skin in *Cyprinus carpio* (scale bar = 5 μ m), Fig. 3 – General aspect of the margin of a caudal lesion (scale bar = 500 μ) Fig. 4 – Detail from swollen epithelial cells in the proximity of a caudal lesion (scale bar = 20 μ m)

Scanning electron microscopy (SEM) investigations [20]: the investigated material consists of small skin pieces with and without lesions. The material was fixed in glutaraldehyde (2%) for 2 hours, osmium tetroxide (1%) for 4 hours and washed with phosphate buffer. After dehydration in a graded ethanol series (40%, 70%, 80%, 90% and 100%) and acetone, the material was critical point

dried with CO₂ (using a EMS 850 Critical Point Dryer), sputter-coated with a thin layer of gold (30 nm) (using a EMS 550X Sputter Coater) and, finally, examined by scanning electron microscopy (Tescan Vega II SBH) at an acceleration voltage of 27.88. Photos were taken from the most relevant aspects.

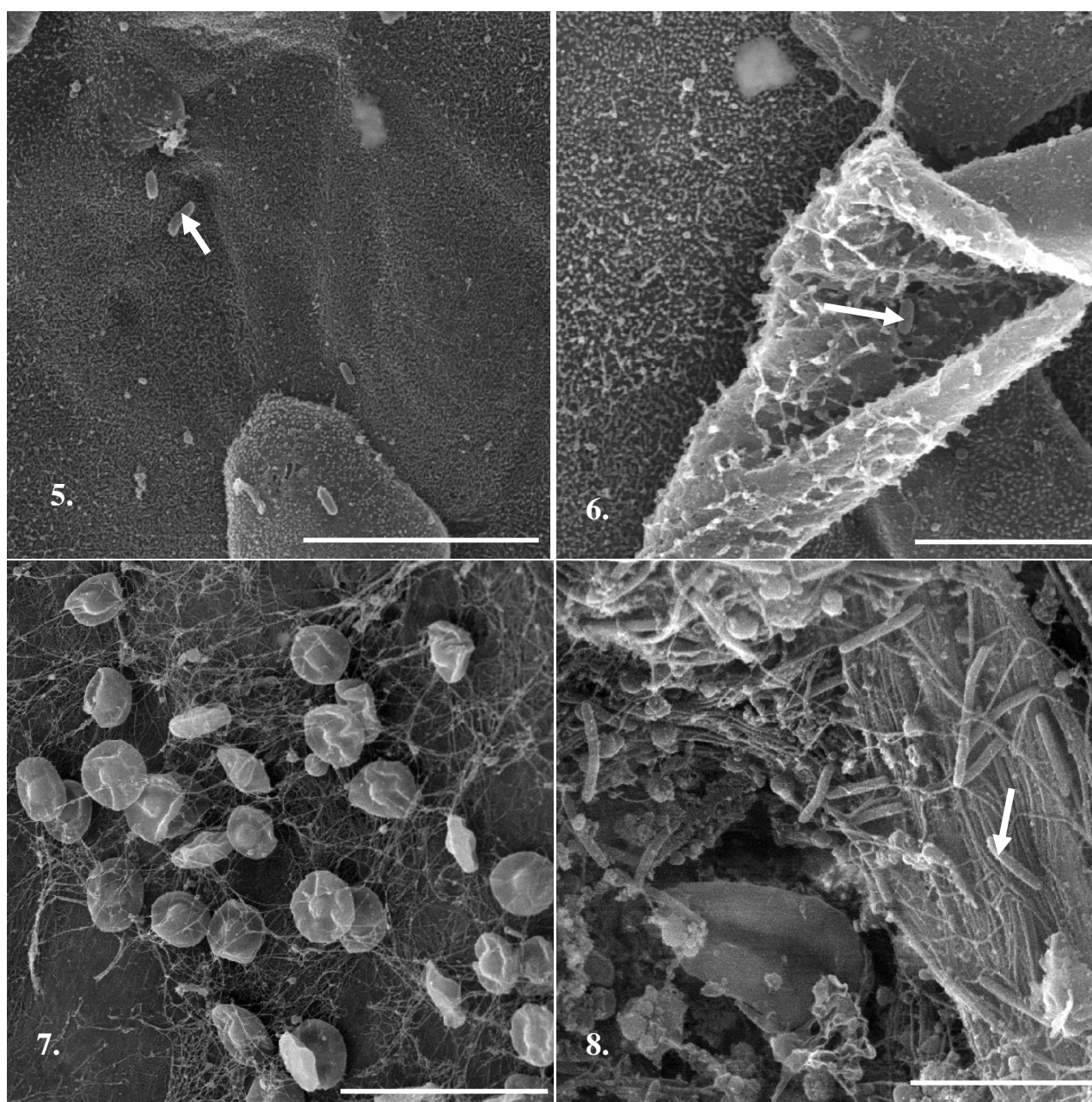


Fig. 5 – Detail from swelling epithelial cell in the proximity of a codal lesion in *Cyprinus carpio*; isolate bacteria could be observed (scale bar = 20 μ m), Fig. 6 – Detail from exfoliated epithelial cell in the proximity of a codal lesion; isolate bacteria could be observed (scale bar = 10 μ m), Fig. 7 – Detail from the proximity of a lesion; red blood cells included in a fibrin network (scale bar = 20 μ m), Fig. 8 – Detail from the central part of a lesion; numerousness bacteria – bacilli – could be observed (scale bar = 5 μ m)

III. RESULTS AND DISCUSSIONS

Fish skin is very important in the defense against bacterial infections. Because it is not keratinized, the protection regards pathogens is limited compared with the terrestrial vertebrates skin.

In *Cyprinus carpio* different areas from normal skin, lesions and one healed lesions was investigated. The epithelial cells

presents distinctive microridge pattern (figures 1, 2). These ornamentations form a pattern that is species-specific [21]. Their role exceeding in retain of the mucous substances secreted at the skin surface [21, 22] helps in protecting the fish against bacterial, fungal and parasite attacks. The upper cell layer are not renewed periodically, but are individually replaced when dead.

Under SEM, in the periphery of the lesion (figure 3) the surface epithelium present raised epithelial cells (figure 4).

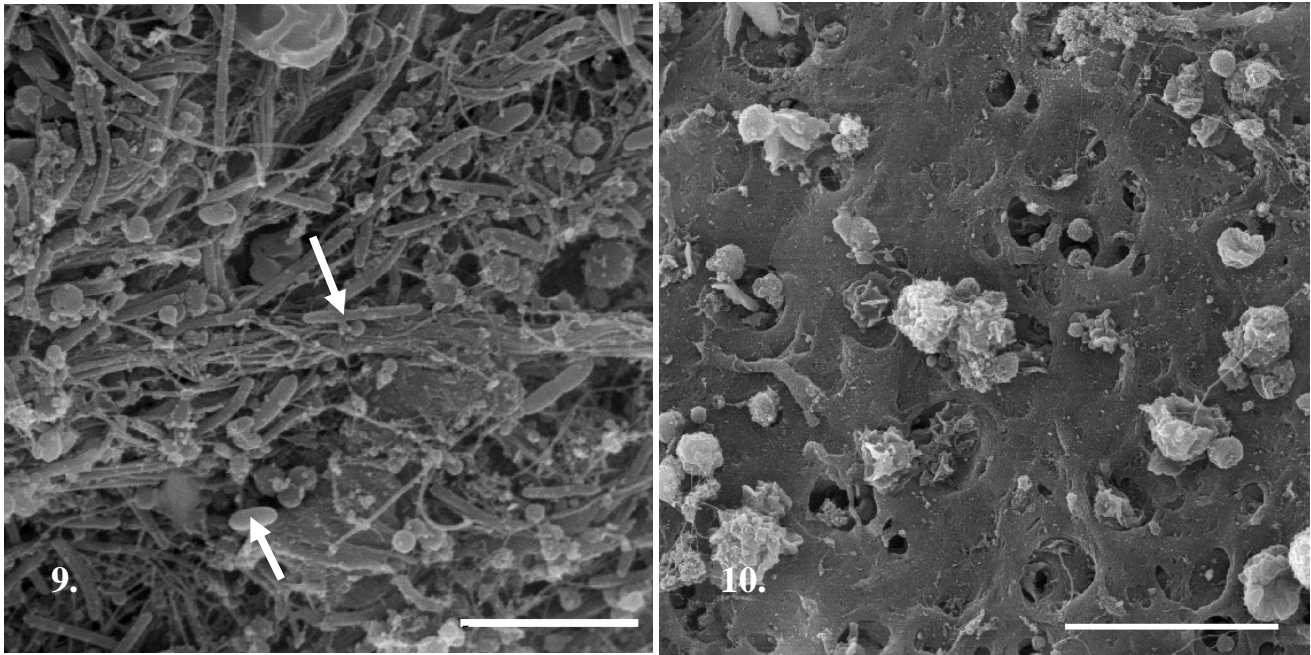


Fig. 9 – Detail from the central part of a lesion in *Cyprinus carpio*; numerousness bacteria, could be observed (scale bar = 5 μ m), Fig. 10 – Detail from the central part of a healed lesion; with blood elements could be observed (scale bar = 5 μ m)

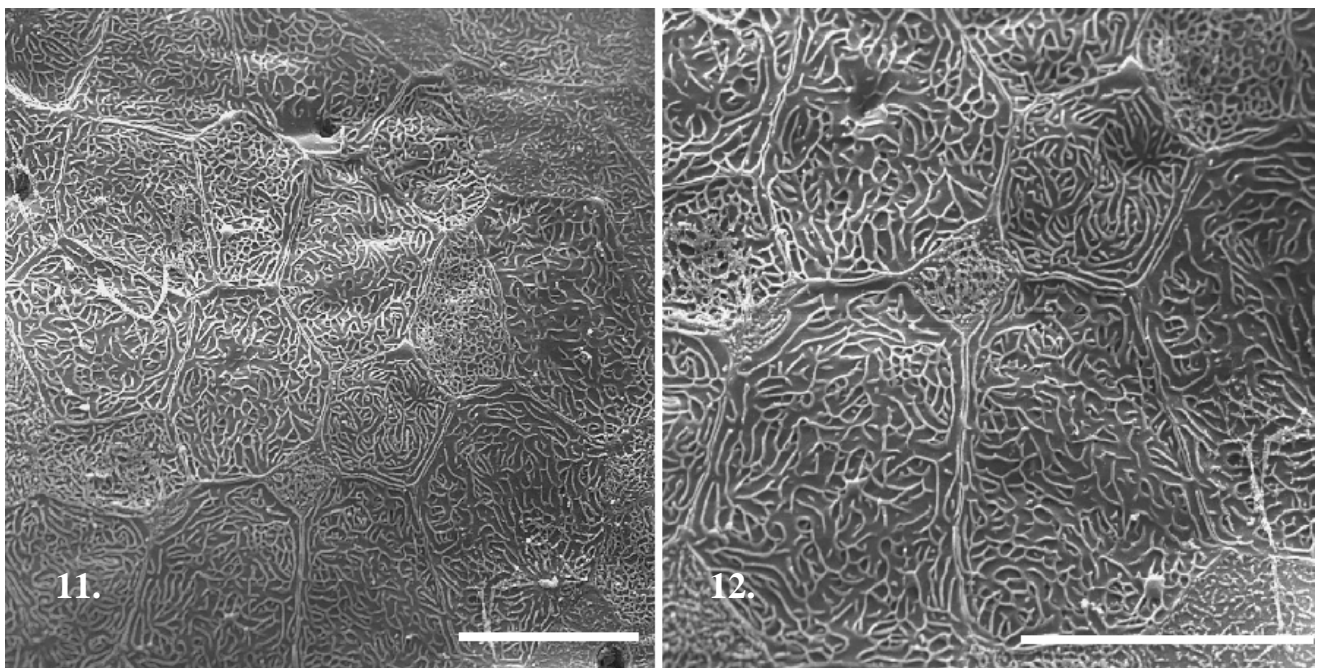


Fig. 11 – General aspect of the normal skin in *Salmo trutta fario* (scale bar = 20 μ), Fig. 12 – Detail from epithelial cells of the normal skin in *Salmo trutta fario*; superficial microridges in parallel formation could be observed (scale bar = 20 μ m)

The epithelium showed evidence changes in the cells with some swollen and exfoliated.

On the unaffected skin, as well as on the modified epidermal cells, isolate bacteria could be observed (figure 5, 6); it is important to mention that the bacteria are observed on cells devoid of mucus (this demonstrate again the antimicrobial role of the mucus for the fish skin). Round bodies, with irregular surface, with may have been lymphocytes were also seen near

the lesion. In the same time, numerousness red blood cells included in a network of thin fibers fibrin (which is a type of protein) are visible in the lesion vicinity (figure 7).

Inside the lesion, a large number of bacteria could be observed (figures 8, 9). The presence of an *Aeromonas* species was determined upon clinical signs and confirmed by microbiological studies (unpublished work). *Aeromonas* preferentially invades previously damaged tissue, typically an

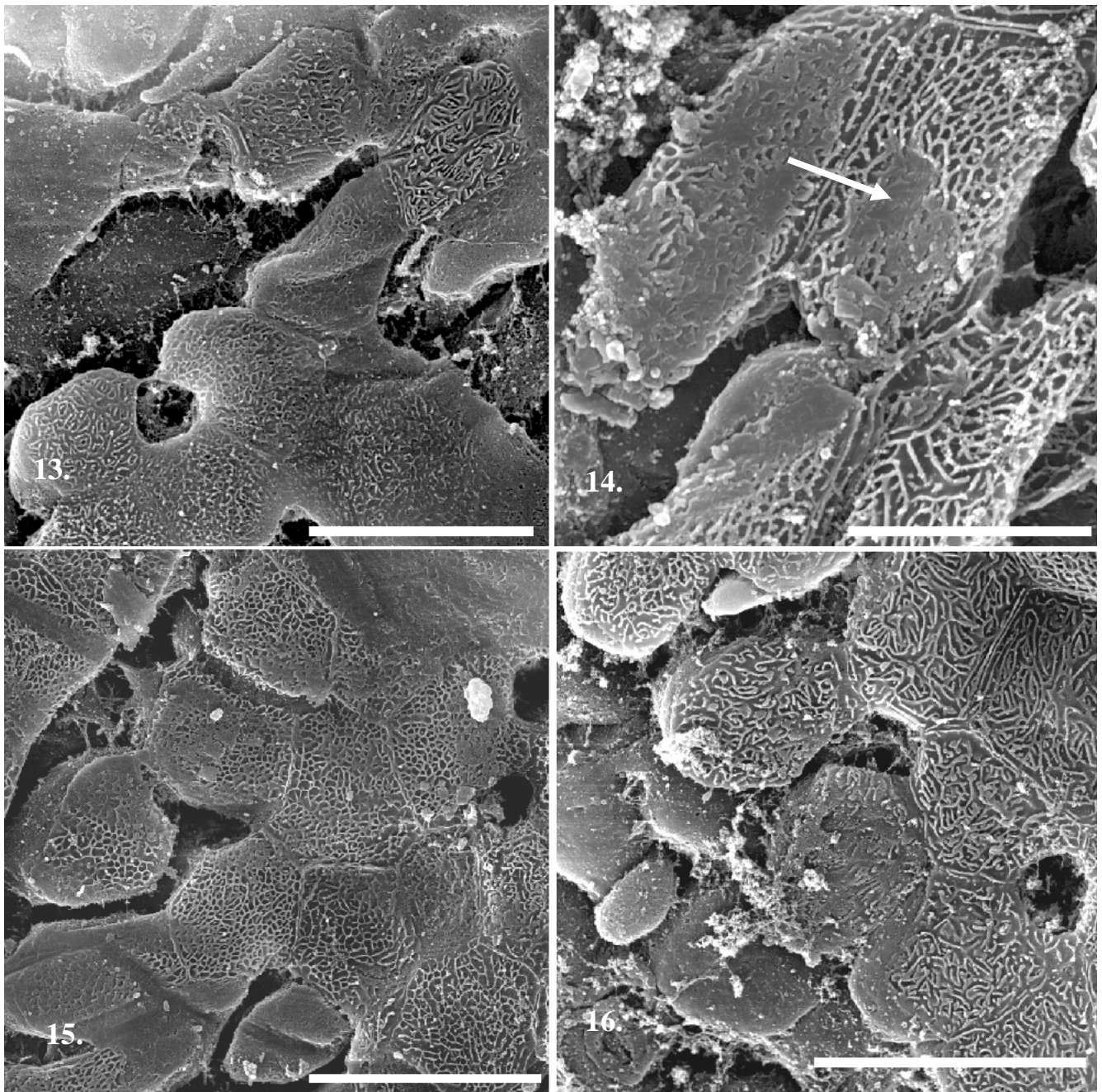


Fig. 13 – General aspect of the margin of a lesion on *Salmo trutta fario* skin (scale bar = 20 μ) Fig. 14 – Detail from swollen epithelial cells in the proximity of lesion – deteriorate microridges could be observed at the surface of the swollen epithelial cells (scale bar = 10 μ m), Fig. 15, 16 – Detached epithelial cells in the vicinity of one lesion (scale bar 20 μ m)

area of erosion. The integrity of the skin plays an important role in protection against bacterial infections.

Bacteria may be destroyed by antimicrobial products (lysozymes, agglutinins) present in the mucus [23, 18, 24, 25].

The examination of healing lesions showed the collagen scar with numerousness blood cell elements, especially leucocytes and few red cells (figure 10). Healing does not involve restoring of the cells with specific ornamentalions

(microridges). An unstructured scar takes the place of the lesion.

The ultrastructure of the *Salmo trutta fario* skin observed by scanning electron microscopy showed at the surface a continuous layer of epithelial cells (fig. 11). It consisted of a mosaic pavement of irregular polygonal epithelial cells of varied dimensions. The superior surface of each epithelial cell was characterized by the presence of a series of microridges

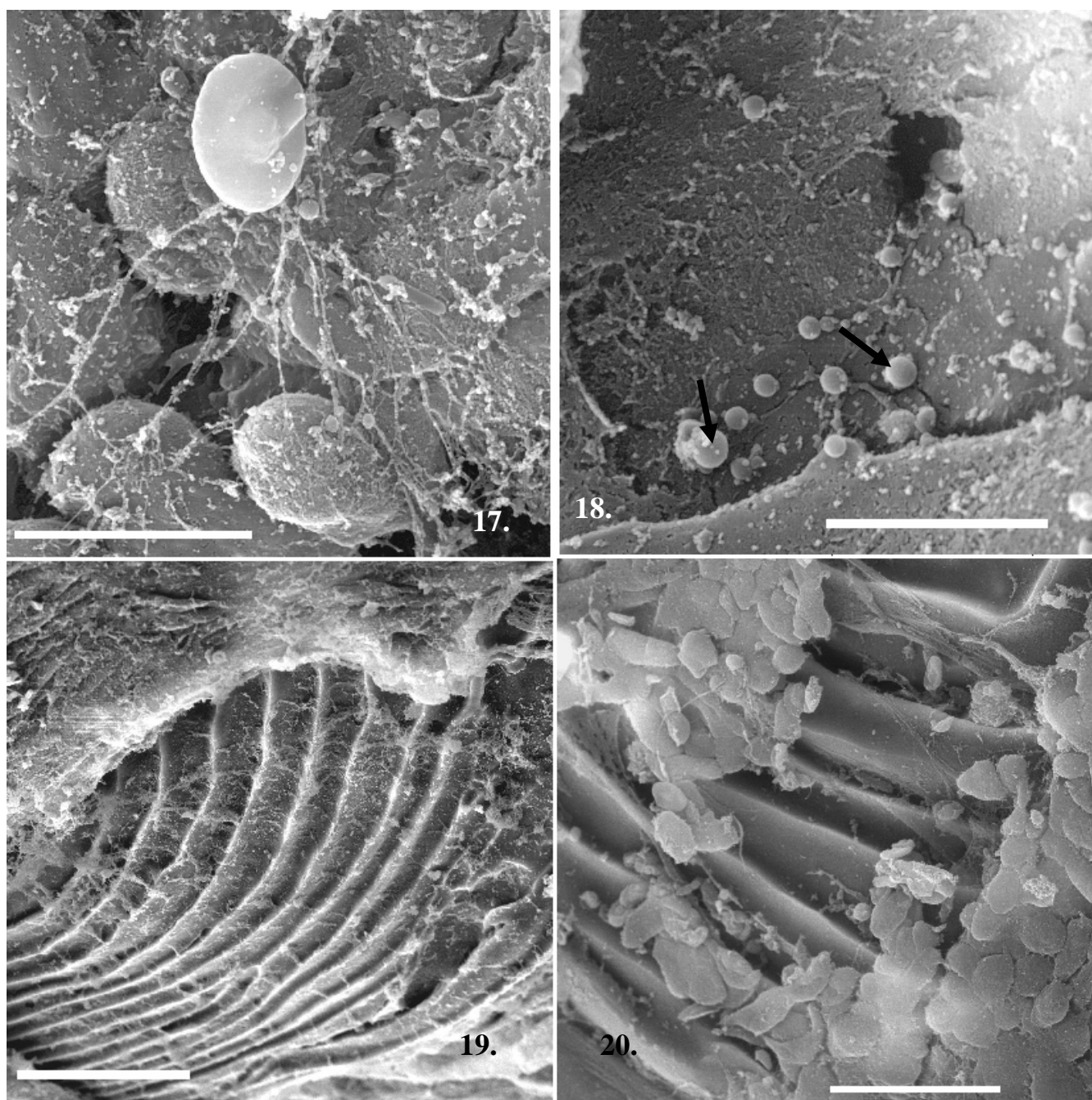


Fig. 17 – Detail from a haemorrhagic lesion on *Salmo trutta fario* skin – a red blood cell caught in a fibrin network could be observed (scale bar = 10 μ) Fig. 18 – Detail from a lesion – numerous bacteria (cocci types) could be observed (scale bar = 5 μ m), Fig. 19 – Denuded scale from the middle of one lesion (scale bar = 100 μ m), Fig. 20 – Detail from the surface of the denuded scale – necrosed isolated epidermal cells are visible (scale bar = 50 μ m)

(fig. 12). The microridges of the cells are smooth, approximately equal in width and sinuous. They were compactly arranged [26]. The mucous cells are numerous.

The skin from the vicinity of the lesions showed marked epithelial changes compared with the healthy skin (fig. 13). The epithelial layer is disrupted and shows swollen pavement

cells (fig. 15, 16). Deteriorate microridges could be observed at the surface of the swollen epithelial cells (fig. 14).

An ulcer is as a break in the skin (a lesion) extending through all the layers, which fails to heal and is often accompanied by inflammation.

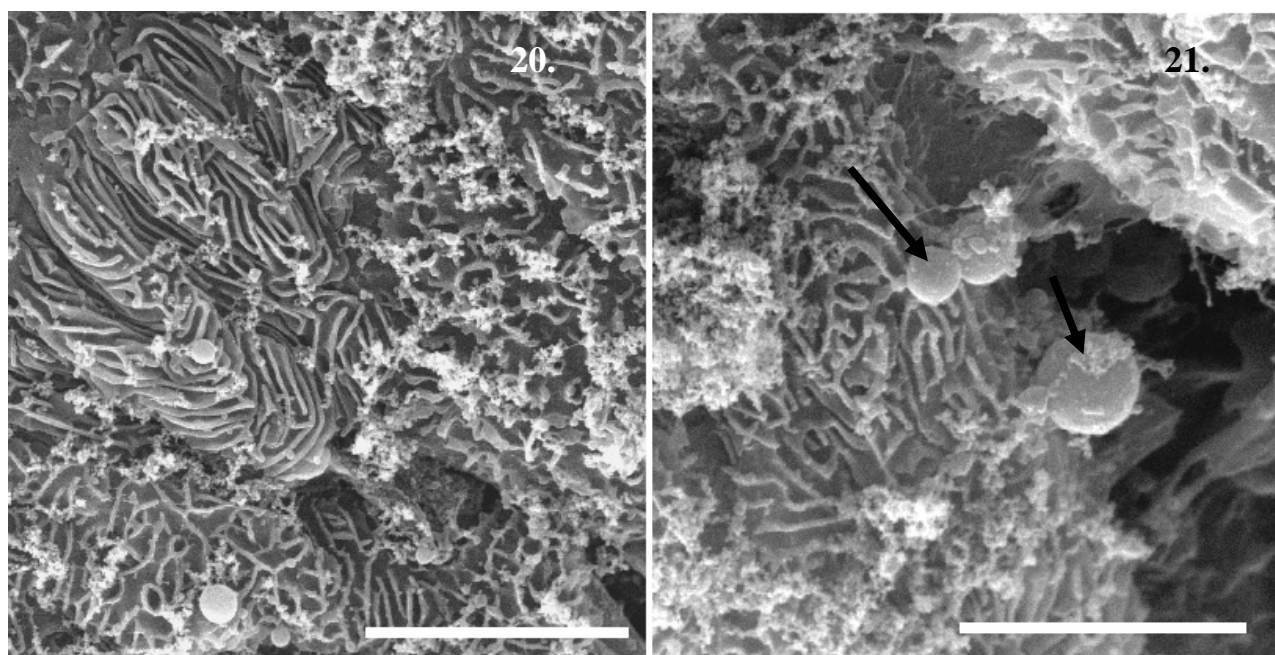


Fig. 21 - Detail from a periphery of a lesion on *Salmo trutta fario* skin – isolated bacteria (cocci types) could be observed; the apical surface of the epithelial cells (covered with microridges) present adherent mucus (scale bar = 10 μm), Fig. 22 – Detail with isolate bacteria (scale bar = 5 μm)

The typical skin ulcer has a central area of tissue erosion that may be shallow or deep – in some cases exposing the underlying muscle. Around the edge of the lesion is usually an area of whitish necrotic (dead) tissue and debris, with a large outer zone of inflammation extending into healthy tissue. The scales surrounding the lesion may be denuded, raised or infected. Without treatment it grows gradually in size. In most, but not all, cases they are caused by opportunistic bacteria already present in the water.

Some lesions are hemorrhagic - on the surface of such lesions were observed many red blood cells - most isolated and embedded in a denser or less dense fibrin network (fig. 17). Isolated bacteria (cocci type) were observed both in the middle of the lesions (fig. 18) and at their periphery (fig. 21, 22).

The scales from the lesion area are partial denudes and the osseous layer are visible on its dorsal side (fig. 19, 20). The circuli and the intercirculus spaces are partially covered by necrosed epithelial cells.

IV. CONCLUSIONS

The present paper investigates the contribution of scanning electron microscopy investigations to a better understanding of fish bacteriosis, with emphasis infections on *Cyprinus carpio* and *Salmo trutta fario* skin. Fish skin is very important in the defenses against bacterial infections. The bacteria multiplication takes place especially after the exfoliation of the epithelial cells. Only rare bacterial cells were observed on intact skin or in the lesion vicinity. The important role of the mucus in antibacterial defense was underlined. The large

amount of mucus (as a consequence of the relative high number of mucous cells observed in both analyzed species) could be an adaptation for keeping the skin surface clean, avoiding clogging, the increased slipperiness reducing friction from water flow and increased efficiency in protecting against microbial attachments. The loss of integrity of the epithelium, typical of this disease, is also a portal of entry for other bacterial or parasitic pathogens.

REFERENCES

- [1] S. Depountis, S. Lamprakopoulos, N. Yfanti and D. K. Yfanti, "Study of an environmental friendly antifouling coating for fish cage nets", *Proceedings of the 2006 IASME/WSEAS International Conference on Energy & Environmental Systems, Chalkida, Greece*, pp. 254-256. May 2006.
- [2] M., Fairuz, H. Hadzli, J. Roziah and A. Anuar, "Fish freshness classification based on image processing and fuzzy logic", *Proceedings of the 8th WSEAS International Conference on Circuits, systems, electronics, control & signal processing*, pp. 109-115, December 2009.
- [3] J. Wen, D. Li and Z. Fu, "A new method for fish-disease diagnostic problem solving based on parsimonious covering theory and fuzzy inference model", *Proceedings of the 5th WSEAS International Conference on Applied Computer Science, Hangzhou, China*, pp. 180-187, April 2006.
- [4] A. Pathirante, G. S. Widanapathirana and W. H. S. Chandrakanthi, "Association of *Aeromonas hydrophila* with epizootic ulcerative syndrome (EUS) of freshwater fish in Sri Lanka", *Journal of Applied Ichthyology*, Vol. 10, No. 2-3, 1994, pp. 204-208.
- [5] J. W. Hawkes, "The structure of fish skin. I. General organization", *Cell and Tissue Research*, Vol. 149, 1974, pp. 147-158.
- [6] G. Bergsson, B. Agerberth, H. Jörnvall, and G. H. Gudmundsson, "Isolation and identification of antimicrobial components from the epidermal mucus of Atlantic cod (*Gadus morhua*)", *FEBS Journal*, Vol. 272, No. 19, 2005, pp. 4960-4969.

- [7] V. Hirvelä-Koski, *Fish pathogens aeromonas salmonicida and renibacterium salmoninarum: Diagnostic and epidemiological aspects*, Academic Dissertation, University of Helsinki, Faculty of Veterinary Medicine, Department of Food and Environmental Hygiene, 2005.
- [8] S. R. Jones, "The occurrence and mechanisms of innate immunity against parasites in fish", *Developmental and Comparative Immunology*, Vol. 25, No. 8-9, 2001, pp. 841-852.
- [9] T. Yano, *The nonspecific immune system: humoral defense*. In: Iwama G, Nakanishi T (eds) *The fish immune system. Organism, pathogen and environment*, Academic Press, San Diego, 1996, pp. 106-157.
- [10] N. Y. Lebedeva, *Skin and superficial mucus of fish: biochemical structure and functional role*. In: Saksena, D. N. (ed) *Ichthyology. Recent research advances*. Oxford & IBH Publishing, New Delhi, 1999, pp. 177-193.
- [11] C. R. Cipriano, "Aeromonas hydrophila and Motile Aeromonad Septicemias of Fish", *Fish and Disease Leaflet*, Vol. 68, 2001, pp. 1-25.
- [12] J. L. Martínez, A. Casado and R. Enríquez, "Experimental infection of Flavobacterium psychrophilum in fins of Atlantic salmon Salmo salar revealed by scanning electron microscopy", *Diseases of Aquatic Organisms* Vol. 59, No. 1, 2004, pp. 79-84.
- [13] D. H. McCarthy, "Some ecological aspects of the bacterial fish pathogen - Aeromonas salmonicida", *Aquatic Microbiology. Symposium of the Society of Applied Bacteriology*, Vol. 6, 1980, pp. 299-324.
- [14] A. S. Kane, D. Oldach and R. Reimschuessel, "Fish Lesions in The Chesapeake Bay: Pfiesteria-like Dinoflagellates and Other Etiologies", *Maryland Medical Journal*, Vol. 37, No.3, 1998, pp. 106-112.
- [15] A. E. Toranzo, B. Magarinos and J. L. Romalde, "A review of the main bacterial fish diseases in mariculture systems", *Aquaculture*, Vol. 246, 2005, pp. 37-61.
- [16] S. Rakers, M. Gebert, S. Uppalapati, W. Meyer, P. Maderson, A. Sell, F. Kruse and C. Paus, "Fish matters: the relevance of fish skin biology to investigative dermatology", *Experimental dermatology*, Vol. 19, 2010, pp. 313-324.
- [17] C. Hellio, A. M. Pons, C. Beaupoil, N. Bourgougnon, and Y. Gal, "Antibacterial, antifungal and cytotoxic activities of extracts from fish epidermis and epidermal mucus", *International Journal of Antimicrobial Agents*, Vol. 20, No. 3, 2002, pp. 214-219.
- [18] A. E. Ellis, "Non-specific defense mechanisms in fish and their role in disease processes", *Developments in Biological Standardization*, Vol. 49, 1981, pp. 337-352.
- [19] C. Lemaitre, N. Orange, P. Saglio, J. Gagnon and G. Molle, "Characterisation and ion channel of novel antibacterial proteins from the skin mucous of carp (Cyprinus carpio)", *European Journal of Biochemistry*, Vol. 240, 1996, pp. 123 - 149.
- [20] A. L. Cohen, "Critical point drying- principles and procedures", *Scanning Electron Microscopy*, Vol. 2, 1979, pp. 303-323.
- [21] L. Fishelson, "A comparative study of ridge-mazes on surface epithelial cell membranes of fish scales (Pisces, Teleostei)", *Zoomorphology*, Vol. 104, 1984, pp. 231-238.
- [22] I. Gostin, A. N. Neagu, V. Vupe, "SEM investigations regarding bacterial infections in Cyprinus carpio", *6th WSEAS International Conference on Energy, Environment, Ecosystems and Sustainable Development (EEESD '10)*, pp. 278-282, October, 2010
- [23] J. B. Alexander, *Non-immunoglobulin humoral defense mechanisms in fish*. In: Manning MJ, Tatner, M. F. (eds) *Fish immunology*. Academic Press, London, 1985, pp.133-140.
- [24] S. K Lau, P. C. Woo, R. Y. Fan, R. C. Lee, J. L. Teng and K. Y. Yuen, "Seasonal and tissue distribution of Laribacter Hong kongensis a novel bacterium associated with gastroenteritis in retail fresh water fish in Hong Kong." *International Journal of Food Microbiology*, Vol. 113, No.1, 2007, pp. 62-66.
- [25] V. Vulpe, C. Misaila, R. E. Misaila and C. Vulpe, "Research concerning the clinic and paraclinic diagnosis in the pathologic estates of the farming fish", *Lucrari Stiintifice Medicina Veterinară, Ed. „Ion Ionescu de la Brad”*, Iasi, Vol. 51, No. 10, 2008, pp. 570 - 572.
- [26] M. Whitear, "Causative aspects of microridges on the surface of fish epithelia", *Journal of submicroscopic cytology and pathology*, Vol. 22, 1990, pp. 211-220.

Associate Professor **Irina Neta Gostin**, Ph. D is currently working in Faculty of Biology, Alexandru Ioan Cuza University of Iasi, Romania since 2009. The current research interests are Electron Microscopy, Plant Anatomy, Citology, Embriology.

Lecturer **Anca Narcisa Neagu**, Ph.D is Technical manager of the ACVAPUR Laboratory for Assessing Water Quality using Bioindicators. The competence areas covered Animal ecomorphology, Animal histology, Animal embryology, Bioindicators of water quality.

Professor **Vasile Vulpe** Ph. D is the head of the Clinics department, Faculty of Veterinary Medicine, USAMV Iasi.