

Digital facial and cephalometric analysis in the orthodontic treatment of a class III high angle patient: a case report

CAMELIA SZUHANEK, RIHAM NAGIB, EDUARD PARASCHIVESCU, DANA CRISTINA BRATU, SILVIU BRAD, DANIEL MALITA

Abstract—In modern orthodontics, diagnosis and treatment planning are becoming more reliant on computer technology, which has seen great improvement in the recent past. Digital record taking has become the preferred method of obtaining diagnosis aids, allowing an easy transition towards digital facial analysis and computer assisted cephalometric measurements. The preliminary diagnosis process and treatment of a 28 year old adult female patient with skeletal class III, increased anterior face height and severe transverse maxillary growth deficit is presented. Digital photographs and lateral cephalometric radiographs documented the soft tissue and skeletal features of the patient. Combined surgical-orthodontic treatment was chosen to correct the skeletal class III. The maxilla was remodeled using fixed orthodontic appliances with mini-implant anchorage, without any rapid expansion or surgically assisted rapid expansion devices. Both arch length deficiency and the significant transverse anomaly were corrected through dentoalveolar remodeling, leaving the sagittal correction to surgery. Final assessment of the results was done by comparing initial digital measurements taken in the diagnosis phase with the digital analysis of the final records taken at the end of treatment. Satisfactory dentofacial aesthetics were achieved.

Keywords—cephalometry, class III, orthodontic diagnosis.

I. INTRODUCTION

Orthodontics is a medical science that deals with the masticatory function and teeth occlusion, being strongly connected to facial aesthetics at the same time. The craniofacial complex can be analyzed with the aid of various imaging techniques chosen depending on the kind of dentofacial deformity the patient exhibits [1].

Class III is a malocclusion widely spread among orthodontic patients with characteristic variations dependent on race and population. Historically, the Class III malocclusion with retrognathic maxilla was described as the “Habsburg jaw” as it has been documented over several generations in this royal family, inspiring research on the genetic nature of the malocclusion. Often patients with skeletal Class III present

specific bone characteristics such as prognathic mandible, large gonial angle, short maxillary length, increased lower facial height. These bone modifications are frequently followed by soft tissue modifications, depending on the severity of the case. The soft tissue characteristics include a retruded upper lip and a protruded lower lip and chin. Maxillary hypoplasia is a growth deficit affecting the development of the maxilla in all 3 planes: anterior-posterior, transverse and vertical. When associated with a normally developed mandible, there will always be a class III skeletal relation [2].

Early surgery can be indicated if functional, aesthetic and psychological factors are severely impacted. Surgical treatment on growing patients does not insure a normal growing pattern after the intervention, and future treatment is a possibility. In adult patients there are two treatment directions that can obtain satisfactory dentofacial esthetics: orthodontic camouflage and orthognathic surgery. Softening the facial appearance is a major reason for surgery in many Class III patients, especially women [3].

Orthodontic camouflage therapy traditionally consists in the proclination of upper incisors and the lingual inclination of lower incisors so to minimize the skeletal underlining anomaly [4]. However, excessive incisor inclination does not only affect aesthetics, it also takes a toll on periodontal tissue health, through probable traumatic occlusal forces. When it comes to soft tissue parameters, most research on facial analysis has depended on 2D imaging methods such as photographs and cephalograms. Normally, postero-anterior cephalometric radiographs are used in the assessment of the skeletal component of facial asymmetry in the transverse plane [6] while lateral cephalograms show skeletal relationship in the sagittal plane. Studies have shown that the frequency of Class III is higher in Asia and the Middle East than in European populations. No significant differences were found between the antero-posterior position of the mandible between the Asian and Caucasian populations, but lateral cephalometric norms are helpful in the diagnosis, treatment planning and the outcome evaluation of adult orthodontic Class III patients [10].

Patients who are satisfied with their facial appearance often choose not to correct the underlining bone deformities [7].

Fear of surgical intervention and higher treatment costs are

Corresponding author : CAMELIA SZUHANEK,
University of Medicine and Pharmacy VICTOR BABES Timisoara
Eftimie Murgu Square no.2, Timisoara
ROMANIA
e-mail: camelia.szuhanek@yahoo.com

two other reasons patients with class III malocclusions choose orthodontic camouflage therapy. This treatment requires high patient compliance and has better results when the comprehensive treatment is instituted in the mixed dentition. Orthognathic surgery can obtain good skeletal relations and a correct tooth inclination, leading to a more stable and functional outcome, resulting in better facial aesthetics as well. The case presented in this report is a 28 year old female who presented herself for an orthodontic consult with the chief complaint of “gummy smile” and unaesthetic facial profile with a negative anterior overjet. She added that her psychological state was negatively influenced by her facial appearance. When asked about class III malocclusions in her family she did not confirm such characteristics in other members of the family. Treatment alternatives were presented after diagnosis and the patient agreed to double jaw orthognathic surgery intervention, but she was reluctant to agree to surgical expansion of the maxilla. As a result an orthodontic approach was chosen to decompensate the deficits in the two arches prior to surgical skeletal correction.

II. FACIAL ANALYSIS

Before any investigation began, a written consent from the patient was taken. Orthodontic photographs were taken before and after treatment: frontal view in relaxed state, frontal view with smile and profile view.

The initial clinical examination of the face revealed facial asymmetry in the transverse plane. To better demonstrate and analyze the asymmetry frontal photographs were cut on the midline. Both halves were duplicated and flipped horizontally resulting in two perfectly symmetrical views. Parallelism between the bi-commisural and bi-pupilar planes was not observed. A slight shift of the chin and the nose was also observed. In the vertical plane, the lower face height was greater than the mid-face height (Figure 1).

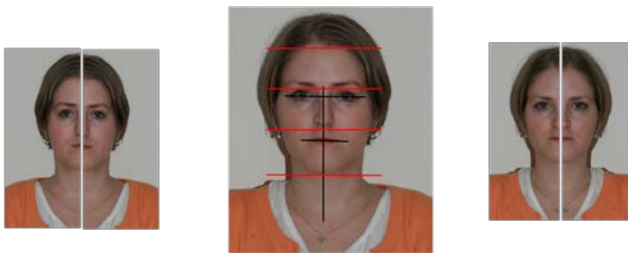

Figure 1: Facial esthetics with perfect symmetry using horizontal inversion of the right side of the face(left) and of the left side(right). Frontal view photograph in relaxed position (middle) .

The patient’s smile was one of the main complaints for which she sought orthodontic correction. There was an increased buccal corridor on both sides and minimal incisor display with “gummy smile”. Due to the lack of transverse development the smile appeared narrow. Facial aesthetics were unsatisfactory. After treatment smile aesthetics drastically

improved. There is no more “gummy smile” and the smile arch follows the lower lip. Buccal corridors have diminished and the bi-commisural line is no longer canted to the right (Figure2).

The initial profile was slightly concave, with a retruded maxilla and a protruded chin. After surgical correction we were able to obtain a convex profile. This profile improvement is evident on the cephalometric analysis that will be detailed below. Lower lip prominence was normal after treatment with an aesthetic relationship to the upper lip (Figure 3).

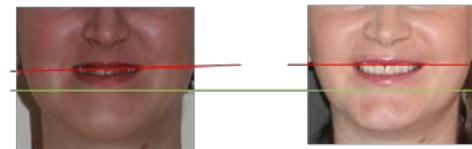


Figure 2: Smile esthetics : horizontal plane is represented by the green line. Red line indicates the bicomisural line initially(left) slightly canted to the left and after treatment(right).



Figure 3: Black line: initial profile. Red line: profile after treatment. Left: Initial profile view photograph. Right: Profile view photograph after treatment.

III. CEPHALOMETRIC ANALYSIS

It has long been known that the diagnosis of severe dentofacial deformities can not be limited at clinical examinations⁸. Although cephalometry has undergone significant changes in the past decades, it is still providing significant prediction and outcome information to the practitioner [9].

Lateral radiographs were taken at the beginning of the orthodontic treatment, after tooth alignment and leveling of the occlusal plane (before orthognathic surgery) and at the end of treatment.

Cephalometric tracings and measurements were done using the Audax Ceph Orthodontic Software Suite (Audax d.o.o., Ljubljana, Slovenia) cephalometri software. Superimposition of the before and after surgery lateral cephalograms show the jaw and profile modifications. Digital analysis of the cephalograms permitted accurate point positioning and correct measurement values The software permitted the choice of analysis and superimposition preferences. Both cephalograms were analyzed using the Tweed-Merrifield standard cephalometric analysis. The before and after surgery radiographs were superimposed over the S-N plane and on Ar point (Figure 4 and 5).

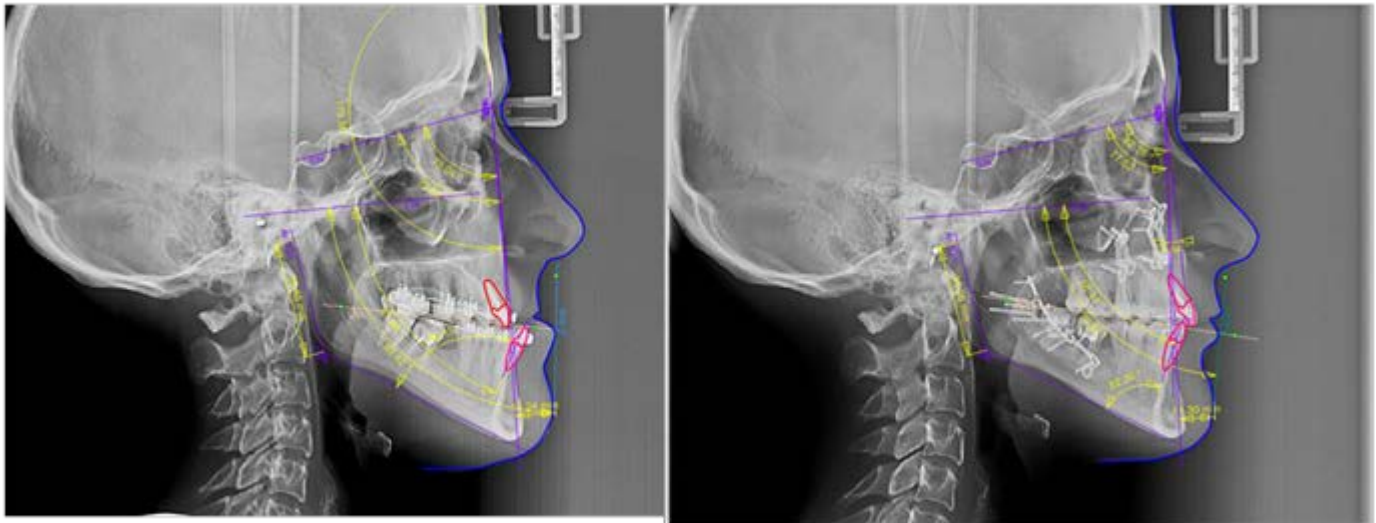


Figure 4: Initial and final cephalometric tracings. Cephalometric tracings of before and after surgical treatment stages provide essential information about soft tissue modifications and skeletal correction in the sagittal plane.

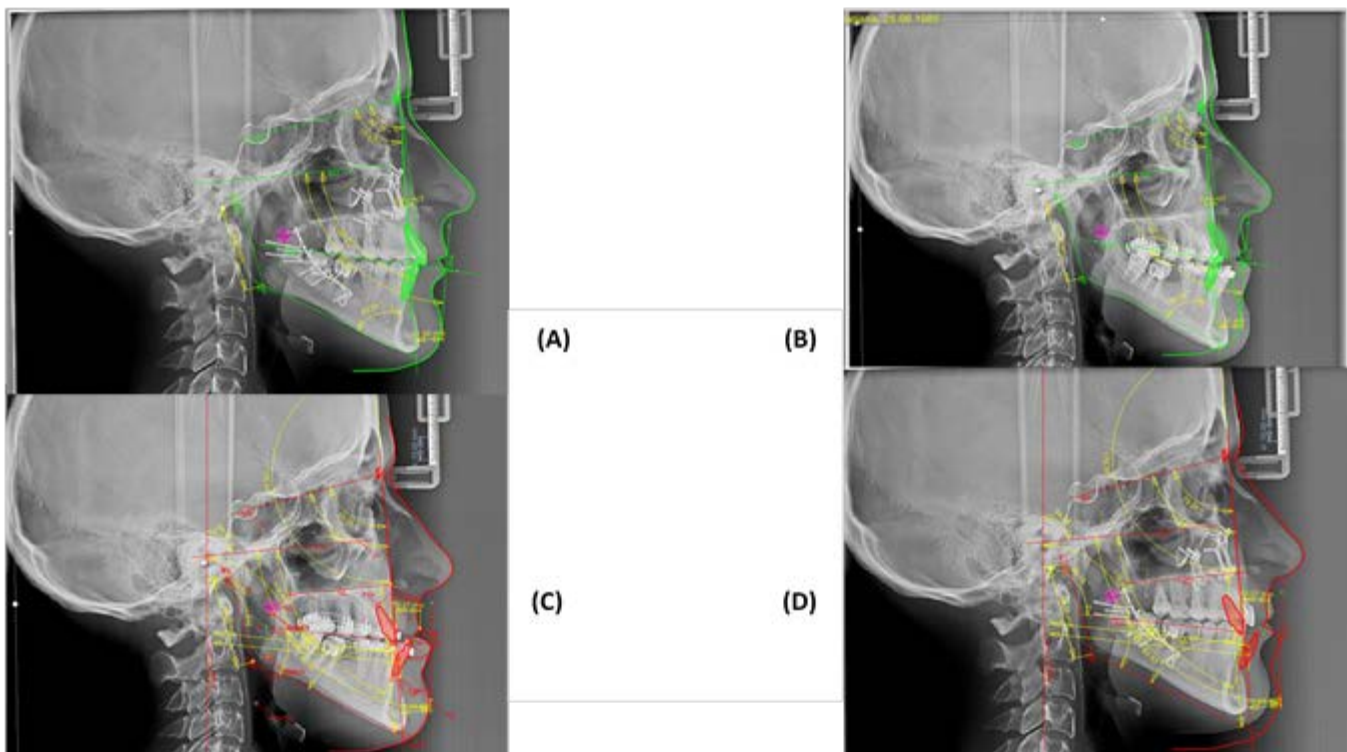


Figure 5: Modifications include upper lip thickness and projection, together with chin projection, leading to an esthetically improved facial profile. Pictures (A) and (B) emphasize profile, skeletal and tooth position correction after treatment: final cephalometric tracing (A) was superimposed over the pre-surgical cephalogram. Upper incisor position and inclination, in combination with LeFort I maxillary surgery offer good support for the upper lip at the end of treatment, giving the profile a straight appearance, compared with the initial slightly concave profile. Lower incisor position and mandibular setback surgery corrected the chin projection and anterior crossbite. Pictures (C) and (D) indicate modification by superimposition of the initial tracing (C) over the final cephalogram (D).

Initial cephalometric analysis revealed a retrognathic maxilla with the SNA angle measuring 78.57° . SNB was 81.32° leading to a ANB equal to -2.75° . The Tweed FMA angle

revealed a hyperdivergent pattern of growth. This led to the conclusion that any further clockwise rotation of the mandible would lead to lip incompetence.

Comparative values of initial and final measurements can be found in Table I.

Table I: Cephalometric computer aided measurements. Initial and after surgical intervention.

Measurement	Value		
	Initial	Normal	Final
Frankfort-mandibular incisor angle °	61.8	68	66.3
Frankfort-mandibular plane angle °	32.0	25	31.4
Incisor-mandibular plane angle °	86.1	88	82.1
SNA °	78.5	82	82.1
SNB °	81.3	80	77.5
ANB °	2.75	3	4.64
AO-BO mm	7.04	2	-1.34
Occlusal plane °	11.7	10	14.0
Z-Angle °	83.4	75	79.8
Upper lip thickness mm	10.0	N/A	8.6
Total chin thickness mm	13.2	N/A	11.2
Posterior facial height mm	39.4	45	36.2
Anterior facial height mm	64.4	65	58.2
Facial height index %	61.2	70	62.4

I. DISCUSSION

Class III skeletal relationships are one of the most complicated orthodontic anomalies in adult patients. Treatment planning for this kind of malocclusion after growth completion often involves a orthodontic-surgical approach and should be established after a complex diagnosis stage[10]-[11]. Human errors usually appear during the radiographic execution and processing. The most often errors are generated by the misplacing of the anthropometrical points, leading to a wrong orthodontic diagnosis [12]. The zoom utility in Audax Ceph Software Suite permitted accurate anthropometrical point placing which led to a correct treatment plan.

A good dentoalveolar response in this case was essential in order to obtain good occlusal relations after orthognathic surgery. The transverse growth deficit and lateral crossbite would have been better corrected with RME devices. Although good results were obtained in the end, dentoalveolar remodeling had its drawbacks throughout the orthodontic treatment. Expansion of the maxilla corrected the lateral crossbite, but it also proclined the upper bicuspids. Palatal cusp interference was observed and a heightening of the vertical dimension. Mini-implant anchorage in the palate resolved the problem, bicuspid inclination became normal and the patient could undergo surgery.

A slight profile improvement was observed even before the orthognathic surgery, with lower lip retrusion and upper lip protrusion. Smile aesthetics were drastically improved in this stage as well.

The satisfactory occlusal and esthetic results were due to

dentoalveolar remodeling and surgical correction of the skeletal anterior posterior discrepancies. Accurate diagnosis led to proper treatment mechanics, which together with sufficient treatment time led to a significant change of both dental and facial aesthetics.

In the management of adult malocclusions an interdisciplinary approach is often needed. Having digital records facilitates communication within the team, and gives access to all patient data from any computer during the initial diagnosis as well as for the study of evolution of the treatment using observations recorded in selected time instants [13]. Moreover, studies demonstrate that the accuracy of measurements carried out using dedicated software on digital radiographs and photographs compared to measurements made by hand on conventional records is much higher. .

II. CONCLUSION

Computer science is very present in modern orthodontics especially in diagnosis and treatment planning, but also in the study of case evolution [11-14].

The introduction of new technology at a fast pace will soon allow the use of a fully electronic patient records, being particularly useful in cases where patients are treated in interdisciplinary teams.

Proper diagnosis and accurate measurements on photographs and radiographs are the key to correct treatment planning especially in severe adult cases, giving the opportunity to avoid unnecessary surgery or prolonged treatment times.

REFERENCES

- [1] Tomaka A, Tarnawski M, Luchowski L, Lisniewska-Machorowska B. Digital Dental Models and 3D Patient Photographs Registration for Orthodontic Documentation and Diagnostic Purposes. *Advances in Soft Computing*, Volume 45, pp 645-652, (2007);
- [2] Larry M. Wolford, Spiro C. Karras, Pushkar Mehra. Considerations for orthognathic surgery during growth, Part 2: Maxillary deformities. *AJO-DO*, Vol. 119, Issue 2, p102-105, (2001);
- [3] William R. Proffit, Tate H. Jackson, Timothy A. Turvey. Changes in the pattern of patients receiving surgical-orthodontic treatment. *AJO-DO*, Vol. 143, Issue 6, p793-798, (2013)
- [4] Bin Cai, Xiao-Guang Zhao, Lu-Sai Xiang. Orthodontic decompensation and correction of skeletal Class III malocclusion with gradual dentoalveolar remodeling in a growing patient. *AJO-DO*, Vol. 145, Issue 3, p367-380, (2014)
- [5] Guilherme Janson, José Eduardo Prado de Souza, Flávio de Andrade Alves, Pedro Andrade, Alexandre Nakamura, Marcos Roberto de Freitas, José Fernando Castanha Henriques. Extreme dentoalveolar compensation in the treatment of Class III malocclusion. *AJO-DO*, Vol. 128, Issue 6, p787-794, (2005);
- [6] McIntyre GT, Mossey PA. Posteroanterior cephalometric analysis of the parental craniofacial morphology in orofacial clefting. *Cleft Palate Craniofac J*, 40:416-25, (2003);
- [7] Steven L. Cureton. A significant transverse discrepancy: A case with a high mandibular plane angle, a severe maxillary arch length deficiency, and significant transverse discrepancy. *AJO-DO*, Vol. 114, Issue 3, p307-310, (1998)
- [8] Moyers RE. *Hand book of orthodontics*. 4th edition. Mosby Publishers, London, (1988);
- [9] Proffit W, Fields HW, *Contemporary Orthodontics*, 4th edition, Mosby Elsevier, St Louis (2007);

- [10] Szuhaneck C, Gâdea Paraschivescu E, Sisu A, Motoc A. Cephalometric investigation of Class III dentoalveolar malocclusion. *RJME* ; 52(4):1343-6, (2011);
- [11] Eduard Gidea Paraschivescu, Camelia Szuhaneck .Surgical-Orthodontic Treatment in Class III Skeletal Anomalies. Proceedings of the World Medical Conference,(2011), Prague, 26-28 September; p227-231;
- [12] Georgeta Zegan, Dragoş Gavriluţ, Cristina Gena Dascălu. The Computerized Establishing of Orthodontic Diagnosis through Radiographic Analysis. *Advances in Computer Science*, (2012), Prague, p522-527
- [13] A. Prochazka, J. Mares, O. Vysata, M. Kasparova, T. Dostalova .Computer Aided Orthodontics Measures Evaluation. *Mathematical Methods and Techniques in Engineering and Environmental Science*,(2011) November 3-5, Catania, Italy, p150-155. G. O. Young, "Synthetic structure of industrial plastics (Book style with paper title and editor)," in *Plastics*, 2nd ed. vol. 3, J. Peters, Ed. New York: McGraw-Hill, 1964, pp. 15-64.
- [14] Szuhaneck C., Glavan F, Jianu R. – Orthodontic biomechanics. *Biomecanica ortodontica*. Ed. Orizonturi universitare Timisoara, 2009.