

# On the Use of Anatomage Table as Diagnostic Tool

Alexandre Taoum, Rihab Sadqi, Mustapha Zidi, Alexandra d'Anglemont de Tassigny,  
Kawtar Megdiche, Nabil Ngote\*

\*Nabil Ngote ([ngotenabil@gmail.com](mailto:ngotenabil@gmail.com)) is with "Université Internationale Abulcasis des Sciences de la Santé", Rabat, Morocco

**Abstract**—Anatomy is one of the most important course in medical curriculum. To be effective, medical student must do several hours of practice on human cadavers. However, today, less and less corpses are available to be dissected. Therefore, Anatomage has developed a virtual dissection table known as Anatomage Table. In addition to filling the lack of corpses and being a very useful tool in anatomy classes, this table can open pathological images. The main purpose of this article is to show the investigation carried out to be able to use the table as a diagnostic tool. Before opening DICOM image into the table, Matlab was used to make the files readable by the Table. This paper deals with the opening of patients pathological images from different type of medical imaging modalities. Indeed, the opening of pathological images turns the Anatomage Table into a very relevant tool in the diagnosis of several pathologies. Experimental 3D reconstruction of pathological patients are presented in order to show the effectiveness of the proposed method. After opening pathological patient files, some hard tissue and soft tissue pathologies were diagnosed thanks to the use of Anatomage Table. That's why the obtained results are largely satisfactory, indicating a promising use in the healing process.

**Keywords**—3D reconstruction, Anatomage Table, Diagnostic tool, Dissection Table, Virtual Dissection

## I. INTRODUCTION

Anatomy is one of the most important courses in medical curriculum, however its educational contribution would not be as effective without practice hours on human corpses [1].

Indeed, cadaver dissection in medical course is for centuries the most used tool to teach anatomy [2]. The Cheikh Zaid Foundation's University, the *Université Internationale Abulcasis des Sciences de la Santé* (UIASS), teach large promotions of medical students.

From the geographical position of the university, in Rabat, Morocco, finding cadaver for dissection courses is very difficult, mainly because of religious reasons. The lack of cadaver in medical courses is felt in other universities of the Kingdom of Morocco [3]. Even in western countries, the number of corpses and hours of dissection have been reduced [4]. To overcome this (lack or absence of cadaver), the Anatomage Table is a very interesting alternative.

Alexandre Taoum is with "Institut Supérieur des BioSciences", Faculty of Medicine, Créteil F-94010, France.

Rihab Sadqi is with Medical Simulation Center of the Cheikh Zaid Foundation, Rabat, Morocco.

Mustapha Zidi is with Bioengineering, Tissues and Neuroplasticity, EA 7377, Université Paris-Est Créteil, Faculty of Medicine, 8 rue du Général Sarraïl, 94010 Créteil, France

Alexandra d'Anglemont de Tassigny is with INSERM U955, équipe 3, Créteil F-94010, France

Kawtar Megdiche is the head of Medical Simulation Center of the Cheikh Zaid Foundation, Rabat, Morocco.

Indeed, Anatomage has developed a virtual dissection table of the human body in real size [5]. Several hundred cases are implemented by the manufacturer in the Anatomage Table. Virtual dissections on the Anatomage Table make its utilisation simple because it didn't need chemical treatment and it is fully reusable [6].

Because of its simple handling, the use of the Anatomage Table in the Cheikh Zaid Foundation provides a solution to the lack of cadaver within the medical curriculum. In fact, the use of the Anatomage Table make the understanding of the whole body easier to explain to young doctors, medical students or even patients [7]. Nevertheless, studies show that most of the medical students prefer working on 3D images instead of 2D images [8].

Otherwise, the Cheikh Zaid Foundation Medical Simulation Center welcomes medical training from the first year to the sixth year of medicine. In the clinical teaching curriculum, medical students are expected to study, specify, diagnose and manage radiological images from several medical imaging modalities such as MRI, CT, ultrasound and standard radio. The use of the Anatomage Table at the simulation center of the Cheikh Zaid Foundation will be made mandatory on september 2018.

For now, the most used side of the Anatomage Table is its pedagogical side. Therefore, creating a new library by implementing pathological images from real patients is desired to make this device more useful in medical curriculum, especially in anatomy courses. Some authors have already implemented pathological images in their Anatomage Table [7] with, as main objective, to make Anatomage Table a very effective tool in the medical courses teaching, by implementing the pathological image of real patients in the Table and comparing them to non-pathological images.

In this paper, we propose a new approach based on the use of Anatomage Table as a diagnostic tool. In fact, after opening pathological files on the table, the idea of using Anatomage Table as a diagnostic tool was immediately raised. Indeed, creating a 3D reconstruction of a patient from 2D scans could make the Anatomage Table a major tool helping doctors in their patients treatment. In fact, a 3D reconstruction of pathological image can improve quality, speed and reliability of diagnosis. The major novelty is the use of virtual dissection table as a tool for diagnostic. Using Anatomage Table for choosing an appropriate treatment is possible like in preoperative strategy. Indeed the 3D reconstruction can help surgeon make decisions more adequate with the patient's pathology.

The approach of the research is made by opening to pathological cases, one with hard tissues opened with computerized tomography (CT) and one with soft tissues opened with magnetic resonance imaging (MRI)

The rest of paper is organized as follows. Section II depicts materials and methods. Section III is devoted to the results and discussion. Finally, conclusions are mentioned in Section IV.

## II. MATERIALS AND METHODS

### A. The Use of DICOM files in medical imaging

Digital Imaging and Communication in Medicine (DICOM) is a standard file type used in medical imaging. The standardization of medical imaging was necessary to harmonize all the files obtained through medical imaging devices. DICOM file has an Unique Identifier (UID) which can provides information on the origin of the file, such as the image acquisition technique [9]. This file type is usable on any operating system such as Windows, IOS, or Linux.

### B. Matlab's previous processing on DICOM files

The DICOM files studied here are from Cheikh Zaid Hospital's patients. Each file is anonymized to ensure the hospital's best privacy to the patient [10]. To anonymize DICOM files, Matlab 2018a is used.

The Matlab function used to anonymize is "dicomanon ()". The previous command creates an anonymized copy from the starting file (Fig. 1). This function can also be used on a series of files located in the same folder. It also keeps the hierarchy of files.

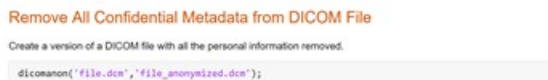

Fig. 1 Screenshot of Matlab's code creating the anonymized copy of file.dcm which is named file\_anonymized.dcm

### C. Opening DICOM files on the Anatomage Table

The operating system Table Anatomage is Windows 6.1.7601. The application used to perform a virtual dissection of the human body is TableEDU 4.0 which is pre-installed on the Anatomage Table by the manufacturer.

TableEDU 4.0 is able to read and open multiple DICOM files [11] at the same time. Each DICOM file represents a 2-dimensional layer of the studied body part. Grouped in the same folder, the application will read all the DICOMs located in this folder, and will try to reconstruct in 3 dimensions, layer by layer, the part of the body revealed by the medical imaging modality. To open DICOM files on the Anatomage Table, the application toolbar and its "OpenFile" action are used. After choosing the folder, and tapping on one of the DICOM files located in it, the volume reconstruction begins.

### D. Adding the extension to the DICOM files

By retrieving USB key files from Cheikh Zaid Hospital's medical imaging services, the files are all recognized by Windows as DICOMs. However, for limiting virus transmission, the safest way to recover files from the hospital is to burn them to CD-ROM and then copy them on a personal computer. Although safer, this method of recovering files makes the recognition of these impossible by Windows directly.

To read them on windows, files must be opened by an executable file copied at the same time on the CD-ROM, autorun.exe. However, to make the Anatomage Table able to read these files, windows must recognize them as DICOM and not of type "file" (fig. 2)

Nom	Modifié le	Type	Taille
19714689	12/07/2018 10:46	Fichier	111 Ko
19714700	12/07/2018 10:46	Fichier	111 Ko
19714711	12/07/2018 10:46	Fichier	111 Ko
19714722	12/07/2018 10:46	Fichier	111 Ko
19714733	12/07/2018 10:46	Fichier	111 Ko
19714744	12/07/2018 10:46	Fichier	111 Ko
19714755	12/07/2018 10:46	Fichier	111 Ko
19714766	12/07/2018 10:46	Fichier	111 Ko
19714777	12/07/2018 10:46	Fichier	111 Ko
19714788	12/07/2018 10:46	Fichier	111 Ko
19714799	12/07/2018 10:46	Fichier	111 Ko
19714810	12/07/2018 10:46	Fichier	111 Ko
19714821	12/07/2018 10:46	Fichier	111 Ko
19714832	12/07/2018 10:46	Fichier	111 Ko
19714843	12/07/2018 10:46	Fichier	111 Ko
19714854	12/07/2018 10:46	Fichier	111 Ko

Fig. 2 opening the DICOM folder on the CD-ROM

Thanks to the command Matlab 'dicominfo ()', it turns out that these files are indeed DICOM. Windows does not recognize them as such because the .dcm extension is not present on these files. The command prompt is used to change the extension by using the following command "ren \* \* .dcm" (Fig. 3) And all the files are then recognized by Windows as being DICOM (Fig. 4).

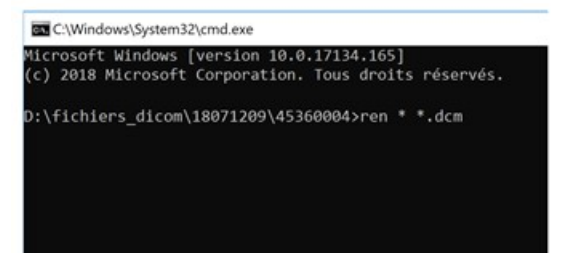


Fig. 3 ren \* \* .dcm command to type in the command prompt (CMD)

Nom	Modifié le	Type	Taille
19714689.dcm	12/07/2018 10:46	DCM File	111 Ko
19714700.dcm	12/07/2018 10:46	DCM File	111 Ko
19714711.dcm	12/07/2018 10:46	DCM File	111 Ko
19714722.dcm	12/07/2018 10:46	DCM File	111 Ko
19714733.dcm	12/07/2018 10:46	DCM File	111 Ko
19714744.dcm	12/07/2018 10:46	DCM File	111 Ko
19714755.dcm	12/07/2018 10:46	DCM File	111 Ko
19714766.dcm	12/07/2018 10:46	DCM File	111 Ko
19714777.dcm	12/07/2018 10:46	DCM File	111 Ko

Fig. 4 The files of Figure 2 are then recognized as DICOM by Windows

## III. RESULTS AND DISCUSSION

## A. Opening DICOM files on the Anatomage Table

After the modification of these files, a patient's head could be reconstructed in 3D thanks to 103 cuts out of the 300 available in the file. A 3D reconstruction of the patient's head could be observed. This head, although consisting of very few cuts, is close to reality. Little reconstruction artifact could be seen such as the halos at the base of the skull (fig. 5)

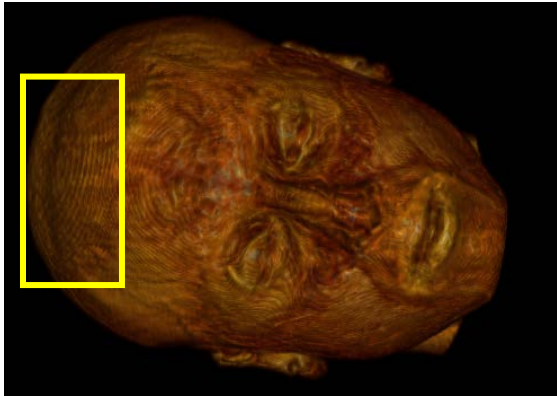


Fig. 5 3D reconstruction of a head of a Cheikh Zaid Hospital real patient, the halos highlighted in the yellow rectangle

These artifacts of reconstructions are due to the small number of slices used to reconstruct the volume in 3D. Indeed, the number of cuts used in volume reconstruction plays a role in the quality, reliability and rendering of 3D reconstruction. After downloading a series of 20 DICOM images of a knee scanner, the quality of the 3D reconstruction is quite poor (Fig. 6).

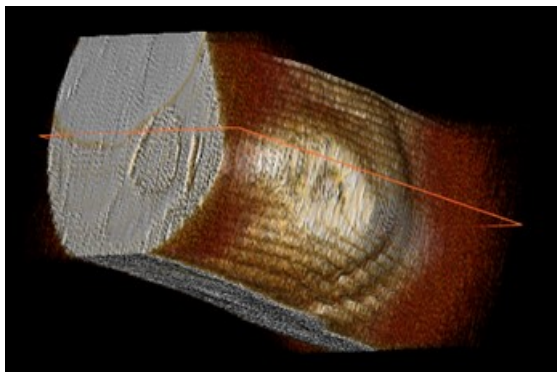


Fig. 6 3D reconstruction of a knee with only 20 DICOM files

All the tools present on healthy patients, are usable on the reconstructions of pathological patients. Dissections and sections can therefore be made on the different volumes reconstructed from images of pathological or non-pathological patients of the Cheikh Zaid Hospital (Fig. 7).

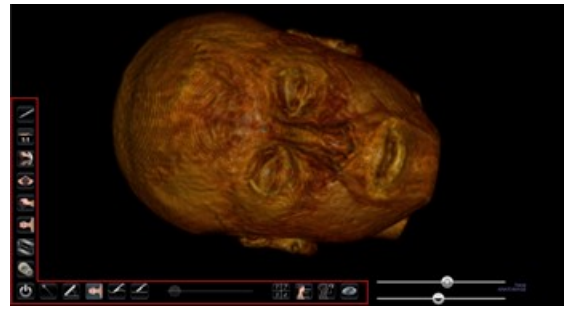


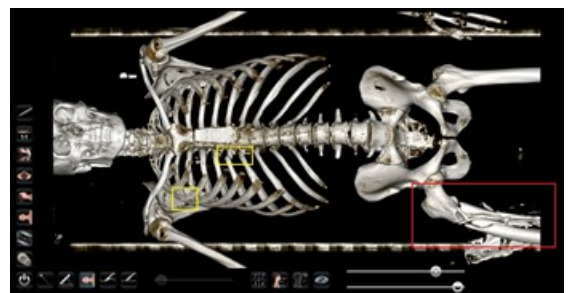
Fig. 7 3D reconstruction of a head of a real patient of the Cheikh Zaid Hospital and highlighting tools usable on the reconstructed volume

## B. Opening the pathological files coming from the tomodensitometry modality on the Anatomage Table

The first pathological patient chosen to be opened on the Anatomage Table is a road polytrauma patient. He has many fractures and cracks all over his skeleton. The recovered DICOM images are those of a "full body scanner". The choice of a CT is appropriate here because the patient has skeletal pathologies, these tissues having a higher density than the other softer tissues of the human body, they stand out better in the scanner modality.



(a)



(b)

Fig. 8 (a) image of the 3D reconstruction of a whole body of a real patient (b) Image of the 3D reconstruction by keeping only the hard tissue with evidence of fractures and cracks.

The most obvious pathology here is the right femur fracture. A 3D reconstruction makes possible to highlight the less obvious pathologies such as fractures or cracks in the ribs that may be missed by a medical student or even an inexperienced doctor, because it is almost not visible on the 2D CT sections. In spite of the long experience of the doctors, the 3D reconstruction allows a quick, easier and more pleasant diagnosis of the pathologies (Fig. 9, Fig. 10).



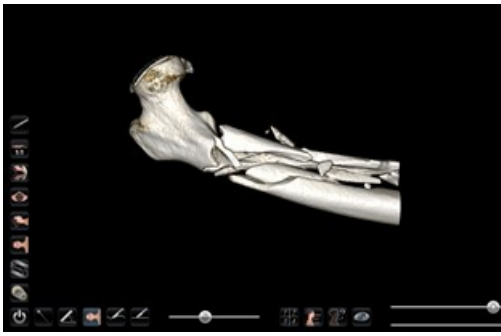


Fig. 9 Zoom on the fractured femur of the patient (red highlighted part on fig. 8(b) )

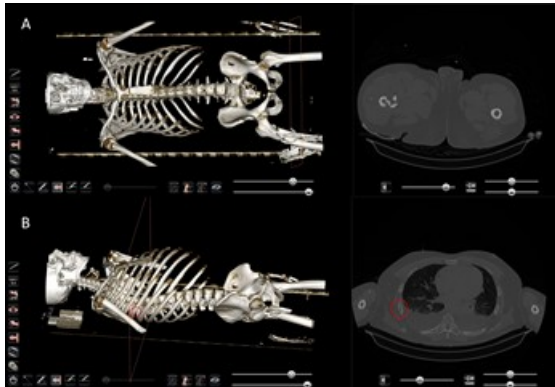


Fig. 10 (a) Whole body plus its 2D cut of fractured femur  
(b) Whole body plus its 2D cut of a cracked rib

In addition to the pathology on hard tissues, thanks to the 3D reconstruction and the use of the plane dissection tool, a cardiac pathology (on soft tissues) had been observed, a slight cardiomegaly exerts a pressure on the lung left (fig. 11). The 3D reconstruction of the Anatomage Table then made it possible to detect an undiagnosed pathology on this patient, transforming the table into a diagnostic tool and no longer only useful for educational purposes.

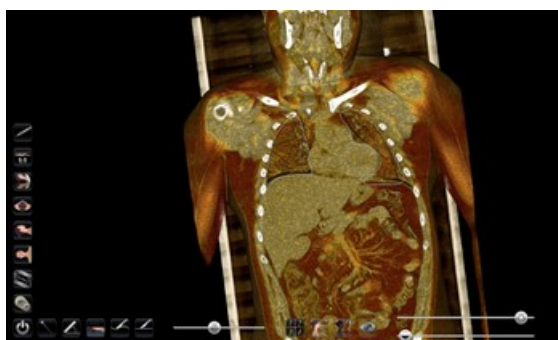

Fig. 11 Soft tissue pathology observed on the polytraumatized patient reconstructed in 3D on the table with the patient's two lungs highlighted

Although a soft tissue pathology has been detected, the visualization quality of these tissues remains low and not very useful. The tissues of the heart and liver have been reconstructed with almost identical density (Fig. 11). Nevertheless, the cardiac pathology is clearly visible because the right lung and the left lung which must be symmetrical are no longer because of the pressure exerted by an cardiomegalic heart on the left lung. Cardiomegaly is

defined as an increase in heart size caused by ventricular hypertrophy [12].

The volume reconstruction of the 2D slices also brings reconstruction artifacts as well as reconstructed volume noise such as the table where the patient is lying down, the plastic headrest but also a towel placed under his right thigh.

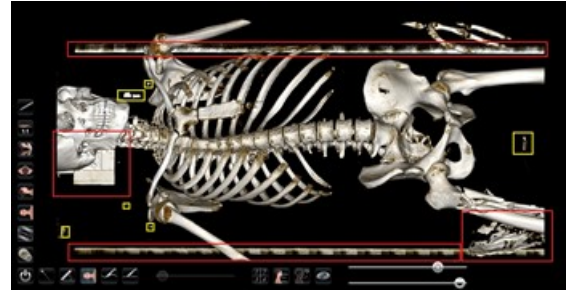


Fig. 12 reconstruction artefacts in red and in yellow the reconstruction noises

With the appearance of reconstruction artifacts and noise, the reconstructed volume has a significant number of undesirable volumes (Fig 12), despite the very good quality of the desired volume. Thresholding or segmentation work or image processing before reconstruction would provide a solution to this problem.

### C. Opening the pathological files coming from the MRI modality on the Anatomage Table

After opening hard tissues pathological files, although a pathology on soft tissues was detected, the visualization of these tissues remains difficult with this 3D reconstruction resulting from a CT modality. The opening of pathological files from MRI acquisition modalities for the visualization of soft tissue pathologies was performed. The first 3D reconstruction performed was that of a pathological patient with a right breast tumor. In addition to the tumor visible in 2D images, 3D reconstruction allows to observe clinical signs such as retraction of the flesh in the breast [13] and a redness (Fig. 13A and 13B).

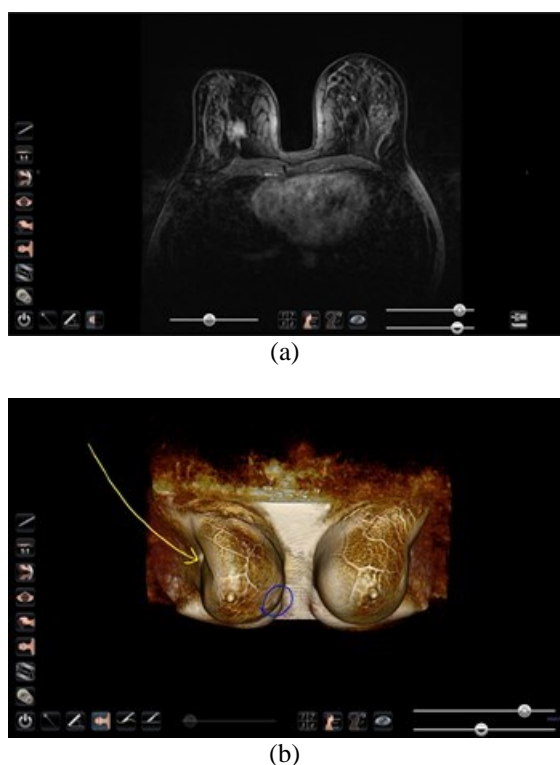


Fig 13 (a) MRI image of the breast of a real pathological patient of the Cheikh Zaid Hospital\_(b) 3D reconstruction of the breast of a pathological patient. The yellow arrow represents the traction of the flesh of the breast and the part surrounded in blue the redness present on the left breast.

Tumor tissue and healthy tissue have different densities, which makes it possible to isolate them on the TableEDU 4.0 application thanks to the two knobs at the bottom right of the screen. After adjustment of these knobs may have begun to observe the tumor mass on the right breast of the patient (Fig 14).

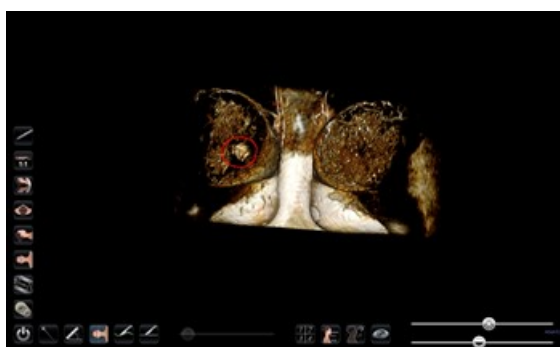


Fig. 14 Tumor mass (circled in red) present on the right breast of the patient

Thanks to the section tools present in the TableEDU 4.0 application, the isolation of the tumor has been achieved. Its spiculous shape and vascularity suggest a malignant breast tumor [14]. Moreover, thanks to the measuring tool, the diameter of the tumor was measured. This tumor measures 18.5mm in diameter (Fig. 15).




Fig. 15 Isolation of the tumor of the patient. Its nebulous shape and size are visible in this 3D reconstruction.

#### IV. CONCLUSION

This paper dealt with the opening of patients pathological images on the Anatomage Table. This table is known for pedagogical purposes, but it is certain that it will become a diagnostic tool in addition to a teaching tool. Indeed, its possibilities of 3D reconstruction of any acquisition mode in medical imaging can perform reliable, fast and easier diagnosis. In fact, even a novice in medicine can see pathologies by the use of this table especially at the fractured bones, and even at the breast tumor observed in the 3D-reconstructed breast. The detection of these pathologies through 2D slices can be very complex. The obtained results seem very promising for pathologies diagnostic by the use of Anatomage Table. However, further investigations must be done toward the generalization of this method to other type of pathologies and that will be very beneficial for healing process.

#### COMPLIANCE WITH ETHICAL STANDARDS

**Conflict of interest**—The authors declare that they have no conflict of interest.

## REFERENCES

- [1] B. H. Fruhstorfer, J. Palmer, S. Brydges, et P. H. Abrahams, « The use of plastinated prosections for teaching anatomy-The view of medical students on the value of this learning resource », *Clinical Anatomy*, vol. 24, n° 2, p. 246-252, mars 2011.
- [2] S.K. Ghosh, « Human cadaveric dissection: a historical account from ancient Greece to the modern era », *Anatomy & Cell Biology*, vol. 48, n° 3, p. 153, 2015.
- [3] M. D. Elamrani, M. M. El Fakiri, M. A. Benhima, et M. K. Choulli, « L'éthique musulmane face à la dissection des cadavres humains pour l'enseignement et la recherche en anatomie », *Éthique & Santé*, vol. 12, n° 2, p. 97-102, juin 2015.
- [4] G. Captier, F. Canovas, et F. Bonnel, « Le corps humain et l'informatique comme outils pédagogiques de l'anatomie », *Morphologie*, vol. 89, n° 286, p. 142-153, sept. 2005.
- [5] J. Brown *et al.*, « Medical student perception of anatomage – A 3D interactive anatomy dissection table », *International Journal of Surgery*, vol. 23, p. S17-S18, nov. 2015.
- [6] I. Decorato, « Anatomage Table : dissection anatomique virtuelle pour l'enseignement de l'anatomie », *Morphologie*, vol. 100, n° 330, p. 119, sept. 2016.
- [7] M. Brucoli, F. Boccafoschi, P. Boffano, E. Broccardo, et A. Benech, « The Anatomage Table and the placement of titanium mesh for the management of orbital floor fractures », *Oral Surgery, Oral Medicine, Oral Pathology and Oral Radiology*, mai 2018.
- [8] S. Tan, A. Hu, T. Wilson, H. Ladak, P. Haase, et K. Fung, « Role of a computer-generated three-dimensional laryngeal model in anatomy teaching for advanced learners », *The Journal of Laryngology & Otology*, vol. 126, n° 04, p. 395-401, avr. 2012.
- [9] Bidgood, Jr WD, Horii SC, « Introduction to the ACR-NEMA-DICOM standard. » *Radiographics* 12:345-355, 1992
- [10] W. Newhauser *et al.*, « Anonymization of DICOM electronic medical records for radiation therapy », *Computers in Biology and Medicine*, vol. 53, p. 134-140, oct. 2014.
- [11] T. M. Custer et K. Michael, « The Utilization of the Anatomage Virtual Dissection Table in the Education of Imaging Science Students », vol. 1, n° 1, p. 6, 2015.
- [12] A. H. Amabile, S. D. Moffatt-Bruce, et R. M. DePhilip, « Trapped lung secondary to cardiomegaly in a 78 year-old male with congestive heart failure », *Respiratory Medicine Case Reports*, vol. 18, p. 4-7, 2016.
- [13] F.-Y. Zheng *et al.*, « Comparison of retraction phenomenon and BI-RADS-US descriptors in differentiating benign and malignant breast masses using an automated breast volume scanner », *European Journal of Radiology*, vol. 84, n° 11, p. 2123-2129, nov. 2015.
- [14] Stavros AT, Thickman D, Rapp CL, Dennis MA, Parker SH, Sisney GA. «Solid breast nodules: use of sonography to distinguish between benign and malignant lesions». *Radiology*. 1995;196:123-134.